

NEXUS™ AORTIC ARCH STENT GRAFT SYSTEM - FIRST EXPERIENCE WITH SENTINEL IN HIGH STROKE RISK PATIENT WITH AORTIC ARCH ANEURYSM



PATIENT INFORMATION

An 80 year old male, high surgical risk patient, with systemic vascular disease.



REASON TO TREAT

A 63mm aortic arch zone 3 aneurysm required an aortic arch stent graft system landing into the ascending aorta (Figure 1). In addition, several endoluminal plaques were observed in the arch and distal ascending aorta (Zone 0c) which posed a significantly higher risk of embolization.

The significantly higher risk of embolization was discussed by the team, and a decision was made to use the NEXUS™ Aortic Arch Stent Graft System, which is introduced and deployed over a through and through guidewire, mitigating increased manipulations in the arch. Its single branch design also enables single dual filter distal embolic protection to protect the whole brain.



DEBRANCHING

A standard rerouting procedure of the left sided supra-aortic trunks to the right carotid artery was performed via supra clavicular incisions some weeks before the planned NEXUS™ implantation.



NEXUS™ IMPLANTATION

The endovascular procedure started by introducing the Sentinel filter system retrograde from the left brachial artery through the rerouting graft, with its distal end in the brachiocephalic trunk and its proximal end into the right common carotid artery (RCCA) (Figure 2). After full systemic heparinisation, the larger proximal filter was opened, facing antegrade blood flow, whilst the distal filter remained closed at the origin of RCCA. NEXUS™ implantation was successfully performed according to IFU. During the procedure, ACT value was maintained > 350". The filter was removed after the NEXUS™ Stent graft deployment and ex-vivo examination of the filter showed probable thrombus but no atherosclerotic particles inside the mesh.



PROCEDURAL OUTCOME

Postoperative cerebral imaging didn't reveal any sign of stroke, hemorrhage or respective micro bleeds, but slight signs of amyloidosis. Some days later, the patient was discharged home.



PHYSICIANS COMMENT

In our original experience, the Sentinel showed to be a fast track system that could be positioned retrogradely into the right common carotid artery without interfering with the NEXUS™ Stent Graft system. In addition, our experience confirmed the NEXUS™ Aortic Arch Stent Graft System to be a smooth system to introduce and deploy with no atherosclerotic embolization despite an endoluminal anatomy that strongly suggested high-risk for stroke.

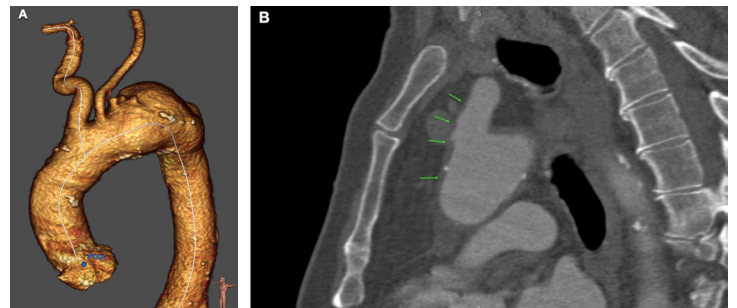

Figure 1.

- (A) Three-dimensional reconstruction created from pre-operative computed tomography angiogram showing the anatomy to be treated
- (B) Sagittal view from computed tomography angiogram illustrating the endoluminal plaques

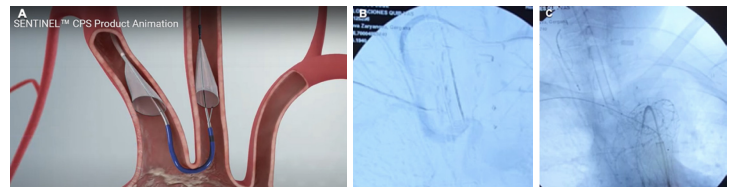


Figure 2.

- (A) The Sentinel CPS Filter System showing dual filter option concept from promotional animation
- (B) Sentinel placement retrograde through the bypass from the left brachial artery
- (C) Sentinel positioning with no contact interaction possible with the NEXUS™ branch



Dr. José Gil-Sales
Angiologist & Vascular Surgeon



Dr. José Porto Rodríguez
Head of Angiology & Vascular Surgery

Hospital Universitario Puerta de Hierro Majadahonda
Madrid, Spain